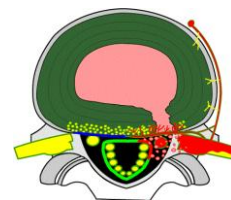


## Disc Herniation: One Name, Many Meanings

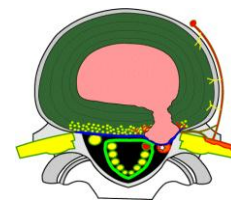
My last newsletter reviewed internal damage of the intervertebral disc in the absence of herniation. In this newsletter, I will review the progression from internal disc disruption to a “Disc Herniation”. I use quotation marks when mentioning a disc herniation because the terminology itself is nondescript and covers an entire process of disc pathology. While lay people find the term easily understood, it does not adequately describe the pathology or its potential implications in a clinical setting or a medical legal setting.

The conversation starts with the commonly used terminology when discussing abnormalities of disc anatomy. As discussed last month, internal disc disruptions (IDD) involve damage to the disc annulus with circumferential and radial tearing; usually associated with disc desiccation (dehydration). The IDD process is pre-herniation but not necessarily painful. We described the IDD pain as being discogenic (originating from the disc itself). The generic term “disc herniation” represents the progression of the pathology beyond the internal boundaries of the disc. It begins at the point where the disc starts to deform from its normal anatomical structure. The descriptive terms range from less severe to more severe including bulges, protrusions, prolapse/extrusion, and sequestration. They can be categorized as contained or non-contained when referring to the integrity of the annulus outer layer and its ability to “contain” the nuclear material. While the full range of disc herniations can result in discogenic pain just like the IDD, it can also result in neurogenic pain coming from direct insult of the neurological structures. In addition to the size and shape of the herniation, discs are often described by their location as being central, para-central, lateral, far-lateral and foraminal. Below is a brief description of the various type of disc herniation.

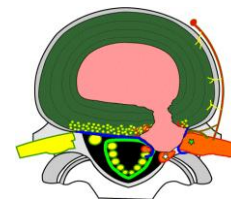
**Disc Bulge:** This is the first step in the progression from IDD. It represents a mild change in the shape of the outer disc and maintains the integrity of the annulus. While sometimes considered to be a normal variant when seen at multiple levels, it can be significant when observed only at one level, implying that it is not part of the patient’s normal anatomy. Bulges can be focal or broad based. Their significance can vary and has much to do with the shape of the spinal canal as well internal ligament structures



**Disc Protrusion:** The protrusion represents a more significant deformation of the outer annulus and gives greater probability that the deformed disc can distort or impinge upon the neurological structures of the spinal cord or nerve roots. This is still considered a contained disc as the outer annulus is intact, maintaining the nucleus within the disc margins. Protrusions are more likely to contact neurologic structures and cause neurologic symptoms and findings. These findings, when present, will vary depending if the spinal cord, nerve root or both are being sufficiently compressed.

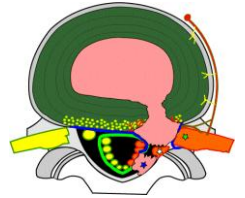


**Disc Prolapse or Extrusion:** At this point in the progression, the pressure from the nucleus is sufficient to break through the outer most fibers of the annulus. The likelihood of nerve or cord compression is greater and there is now a probable chemically mediated inflammation as



a result of the foreign nuclear material. While the protrusion is non-contained, it still maintains its integrity with the rest of the nuclear material. These are often surgical.

**Disc Extrusion and Sequestration:** This is the last stage of the disc herniation process. The disc's nuclear material has breached the outer wall of the annulus and entered the epidural space. When sufficient nuclear material extrudes, it can fragment and the sequestered fragment can migrate. Sometimes the fragment migrates caudally or cephalically (down or up). If it migrates laterally, it can result in narrowing the neural foramen, the hole where the nerve exists, resulting in nerve root compression. Although often surgical, the prognosis for an extruded and sequestered disc can be favorable as the body may attack the sequestered fragment as a foreign body and resorb it over time.



All of these disc lesions have the potential for neurologic compromise. Factors which need to be considered include the size, location and direction of the herniation. The shape and integrity of the spinal canal and foramen play a role. Degenerative changes of the facets and vertebral body further determine the effect of a herniation on neural structures. Soft tissue changes of the ligamentum flavum (a ligament within the canal can lead towards a worsened prognosis).

It should be noted that in 2001 the North American Spine Society, American Society of Spine Radiology, and American Society of Neuroradiology formed a combined task force and recommended a paper published in Spine (Volume 26, Number 5, pp E93–E113) by David F. Fardon, MD, and Pierre C. Milette, MD. The paper titled **Nomenclature and Classification of Lumbar Disc Pathology** modified many of these definitions and there is wide use of both terminology approaches in reports you may see. The paper can be downloaded at this web site <http://www.spine.org/documents/nomenclature.pdf>