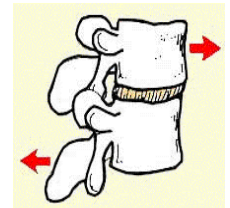


Shear Mechanism Effect of Rear End Impact

Of all the forces applied to the cervical spine in a rear impact injury, none is more injurious than horizontal shear. It is a force that is rarely seen elsewhere and one that nature probably never intended humans to endure. An understanding of the normal movements of the spine can help doctors and attorneys explain why the injury mechanism of a rear impact has such long standing and serious effect on patients

Shear is defined as a deformation of an object in which parallel planes remain parallel but are shifted in a direction parallel to themselves. Biomechanically speaking Shear forces involve the application of a load parallel to the vertebral surface.



In prior newsletters I described how rear end impacts result in a rapid flattening of the cervical spine that results in compression of the spinal structures. The compression itself is potentially injurious but the spine is designed to absorb some of the compression by deformation of the contained disc and the associated fluid dynamics. It is the combined forces of compression and then shear that result in the significant injuries we see in these otherwise “low impact” collisions.

These combined forces usually have their greatest effect within the first 100-125 milliseconds, and generally prior to the time the head makes contact with the head restraint. In some cases, as a result of ramping, the height of the occupant, or a head restraint that's adjusted in the down position, the head may extend over the head restraint and, given sufficient impact velocity, hyperextension may occur. In most cases, however, injury occurs before this point and therefore hyperextension is not a prerequisite for injury. This “new” theory of “whiplash” replaces the old requisite of hyperflexion/hyperextension mechanisms.

In addition to disc injuries, It should be noted that these rapid compression and shear forces result in stretching of joint capsules and vertebral arteries. It also violently and acutely alters the normal curves of the cervical spine resulting in **segmental hyperextension** at lower cervical levels and **segmental hyperflexion** in the mid to upper cervical levels. This rapid change in motion and segmental (rather than global) excessive movement can result in long-term pain and biomechanical compromise as a result of ligamentous sub failure and disc disruption.

Depending on the occupant's kinematics and the nature of the crash, forward kinematics can be just as potentially injurious as the rearward kinematics. For example, if the occupant's struck vehicle then collides with a vehicle in front of it, a secondary impact, the injury kinematics may be compounded with a flexion bending moment superimposed upon the extension moment.

Naturally, muscles can also be injured,. The nerve roots and brachial plexus can be stretched. Brain,

brain stem and spinal cord injuries can result. Disc separations from vertebrae (rim lesions), along with small fractures, significant hemarthroses, and synovial capsule injuries to facet joints, have been observed at autopsy in persons who survived their injuries, but died later of other causes. **In many cases the lesions seen were not visible on radiographs**, even in retrospect.

Recently, an intriguing new hypothesis for injury has been tested. Cerebral spinal fluid pressure gradients in pig spines subjected to extension motions with angular displacements and durations equivalent to those seen in typical cervical acceleration deceleration (CAD) trauma. Researchers found pressure pulses 10 times higher than normal. These pulses produce pressure gradient injuries to cervical and upper thoracic dorsal root ganglia which were demonstrable on light microscopy examination and which are postulated as a mechanism of nerve injury. By the way, pigs are used for these studies because of the similarity of the Cervical Spine architecture

Finally, because so many of the symptoms and conditions, like Thoracic Outlet Syndrome, Temporal Mandibular Dysfunction, Post Concussion Syndrome, Carpal Tunnel Syndrome, etc., develop subsequent to Cervical Acceleration Deceleration injury--some developing weeks or months later--CAD syndrome should be looked upon as a process rather than a single event.

It has become increasingly challenging to educate people about the injury potential of these injuries in the absence of fracture and dislocation. The old theory of the neck moving beyond it's limits in a whip like movement is easy to explain but obsolete and inaccurate for most injured victims.